

Outcomes and Complications of Nonunion of Humeral Shaft Fractures Treated with Locked Compression Plate: A Prospective Study

Singh AK^{1*}, Singh V² and Chaurasia RK³

¹Associate Professor, Department of Orthopedics, Government Medical College, Banda, India

²Senior Resident, Department of Orthopedics, Government Medical College, Banda, India

³Assistant Professor, Department of Orthopedics, Government Medical College, Banda, India

***Corresponding author:** Ashutosh Kumar Singh, Associate Professor, Department of Orthopedics, Government Medical College, Banda, India 2/38, Vinamra Khand, Gomti Nagar, Lucknow, Uttar Pradesh, India, Tel: +919616315616; Email: ashu.ortho@gmail.com

Review Article

Volume 1 Issue 5

Received Date: April 06, 2017

Published Date: June 28, 2017

Abstract

Background: Management of nonunion of humeral shaft fractures are difficult. This study was conducted to evaluate outcomes and complications of these cases treated with locking compression plate (LCP) and autogenous bone grafting.

Materials and Methods: Twenty-four patients of non-union of humeral diaphyseal fractures were included in this study. Fracture ends were freshened, reduced, fixed with locking compression plate and auto iliac bone grafting was done in all the cases. Clinico-radiological assessments were done for each case at each follow-up visit. Time to fracture union, union rate, functional outcome and complication such as infection, malunion, delayed union, implant failure and joint stiffness were recorded. Modified Constant and Murley Scoring was used to assess functional outcome of the fracture fixation.

Results: The mean fracture union time was 16.4 ± 5.8 weeks (range 10–48 weeks). This study had 100% union rate. After assessing modified Constant and Murley scoring, 10 cases had excellent functional outcome, 9 had good and 5 had fair functional outcome. The mean Constant and Murley score was 18.74 in the preoperative period (range 0–34) and 81.20 (range 38–98) at the time of final followup. The range of motion at shoulder joint was excellent in 20 and moderate in 4 cases, and the range of motion at the elbow joint was excellent in 22 and moderate in 2 cases.

Conclusion: This study concludes that LCP is a good implant to treat cases of non-union of humeral shaft fractures with good functional outcomes and acceptable rate of complications.

Level of evidence: Level 2 prospective study

Introduction

The nonunion rate of the fractures of humerus shaft has been as high as 8-15% of all humeral fractures [1,2]. There are various reasons for this including infection, distraction at fracture site, soft tissue interposition, unstable fixation, wrong choice of implant, iatrogenic devitalization of soft tissues, inadequate immobilization, open fractures, comminution and osteoporosis [3,4]. Various devices used in treatment of humeral diaphyseal non-union are limited contact dynamic compression plates, locking compression plate (LCP), humerus interlocking nail, Ilizarov external fixators and bone graft struts [5,6]. Open reduction and internal fixation with plating is generally accepted as the best method of treatment for nonunion of fractures of the humerus in the adult with advantages of stable fixation, direct visualization of fracture site and radial nerve, protection of the radial nerve and sparing of the adjacent shoulder and elbow joint from injury and stiffness.

LCP having features of compression and point bone-plate contact (minimum contact) is being used more commonly for fixation of humeral shaft fractures non-union [7] but very few studies have demonstrated outcomes of use of LCP in the management of a nonunion of humeral fractures [3,4,7,8].

The present study is a prospective study of evaluating outcomes and complications of the use of LCP in osteosynthesis of humeral diaphyseal nonunion.

Materials and Methods

24 patients with nonunion of diaphyseal fractures of shaft of humerus were included in this study from June 2014 to September 2015. The protocol of this study was approved by the institutional review board. This study was authorized by the local ethical committee and was performed in accordance with the ethical standards of the 1964 Declaration of Helsinki as revised in 2000. Informed written consent was taken from all the patients. The inclusion criteria were as follows:

- Age >18 years
- diaphyseal humerus fracture non-union

Cases with infective non-union, with associated medical comorbidities, fractures in the proximal and distal 5 cm of the humerus, pathological fractures, undergoing irradiation and chemotherapy were not included in this study. All the cases included in this study were treated with 4.5 mm LCP and cancellous bone

grafting. Surgery was performed under general or regional anesthesia by the two authors with the patient placed in the lateral decubitus position, using the posterior approach. In all cases dissection was carried out down to the non-union site and radial nerve was identified. Both the proximal and distal fragment ends were debrided of all soft tissue and resected back to bleeding bone. Culture was sent. If any implant was present due to previous surgery, it was removed. In cases where plate had been used in primary surgery, LCP with 10-12 holes was used (Figure 1A-1D). Autogenous cancellous graft was harvested from iliac crest in all the cases and non-union of fracture site was filled with this graft.

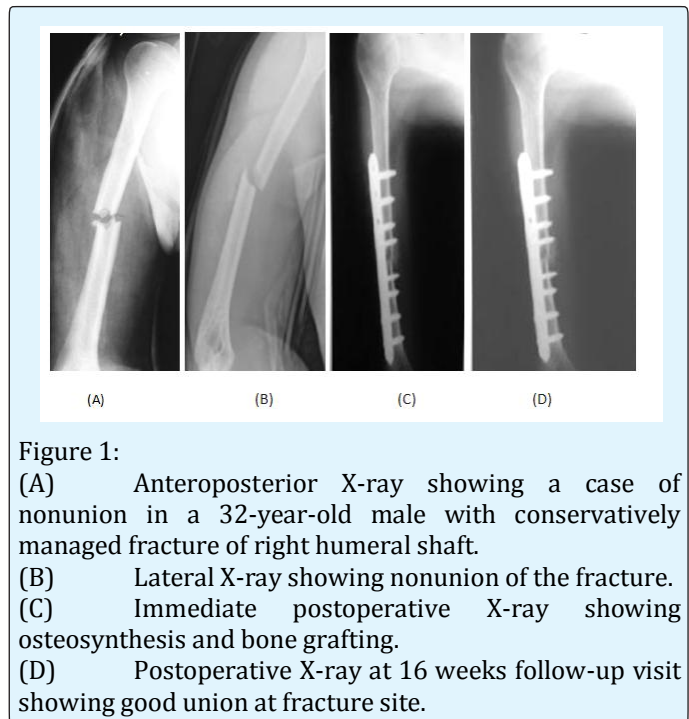


Figure 1:

- (A) Anteroposterior X-ray showing a case of nonunion in a 32-year-old male with conservatively managed fracture of right humeral shaft.
 (B) Lateral X-ray showing nonunion of the fracture.
 (C) Immediate postoperative X-ray showing osteosynthesis and bone grafting.
 (D) Postoperative X-ray at 16 weeks follow-up visit showing good union at fracture site.

In post-operative period, patients were immobilized in a sling, while active and active-assisted range of motion began as soon as tolerated, generally at third day. All patients were followed up at 1-month intervals for the first 6 months after the surgery, then at 2-month intervals for the next 6 months and then at 3-month interval till final follow up visit. Antero-posterior (AP) and lateral radiographs were taken at each follow-up visit. Shoulder and elbow range of motion was assessed at each follow-up visit. Fracture union time, complications and functional outcomes were also recorded. The functional outcome was done by using Modified Constant and Murley Scoring which was recorded before and after surgery and at each follow up [9].

The complications were evaluated in terms of infections (superficial or deep or chronic osteomyelitis), delayed union, non-union, mal union, implant failure, secondary loss of reduction and implant breakage.

Results

The average age in our study was 26.8 ± 8.9 year (range 18–64 years). 12 cases had implant used in primary fracture fixation including DCP, intramedullary nails (Enders nail, Rush nail, Kuntscher nail), multiple pinning, and tubular external fixator, 12 cases included in this study were treated conservatively primarily with plaster or brace (Table 1). Average follow-up period was 18 months after surgery. All the patients attended average follow-up visits. The average time from injury to treatment of non-union was 12.8 ± 4.6 months (4.2–22.8 months).

Characteristics	Study group (n=24)
Age (years)	26.8 ± 8.9 year (range 18–64 years)
Sex (male: female)	15:09
Right: Left	14:10
Average nonunion period	12.8 ± 4.6 months (4.2–22.8 months).
Nonunion cases	
Cases managed conservatively	10
Cases with failure of primary fixation	14

Table 1: Demographic profile of the study

The mean fracture union time was 16.4 ± 5.8 weeks (range 10–48 weeks). This study had 100% union rate. After assessing modified Constant and Murley scoring, 10 cases had excellent functional outcome, 9 had good and 5 had fair functional outcome. The mean Constant and Murley score was 18.74 in the preoperative period (range 0–34) and 81.20 (range 38–98) at the time of final followup. The range of motion at shoulder joint was excellent in 20 and moderate in 4 cases, and the range of motion at the elbow joint was excellent in 22 and moderate in 2 cases.

There was no incidence of superficial or deep infection. One case of iatrogenic radial nerve palsy was reported which recovered fully in 6 weeks. Two case had delayed union which were treated conservatively and they

achieved successful union in 11 months. No case of malunion and non-union was reported in our study. There was no incidence of implant failure in our study.

Discussion

Though majority of fractures of the shaft of the humeral shaft heal uneventfully with conservative treatment [10], the incidence of non-union of the humeral shaft fracture are as high as 13% for both non-operative and operative management [1,2,11]. For these cases, various options available in literature are plates, intramedullary nails, external fixators, with or without bone graft [5]. Locked intramedullary nails have been used in nonunion cases of humeral shaft fractures, but there have been reports to have higher complication rates including pain in the shoulder, subacromial impingement, rotator cuff injury, iatrogenic fracture and failure to achieve union with broken implant [12,13]. Ilizarov external fixation has been used successfully by several authors specially in cases of infective nonunion but there are various disadvantages including bulky implant, pin track infection; chances of neurovascular injury [6,14,15]. Plate osteosynthesis has been shown in various studies to be a better implant for treatment of humeral shaft fractures and cases of nonunion [13,16,17]. Rubel, et al. compared the use of one versus two plates in cases of non-union of humeral shaft fracture in a biomechanical study and concluded that a two plate construct is mechanically stiffer than a single plate construct which may help in cases of non-union of the shaft of the humerus but it demands more soft tissue dissection [11]. Locked plates are now considered a better option with regards to effectively treating long bone non-union in the upper limb [18].

Various studies have achieved good union rate in these cases. Ring et al. reported 100 % union in all the 24 patients of non-union of humeral diaphysis fractures treated with LCP [7]. Kumar et al. in their prospective study, used LCP osteosynthesis and autologous bone grafting in 24 patients with non-union of humeral shaft fractures following failed internal fixation and reported union in 23 patients [19]. They concluded that LCP is a reliable implant for achieving union and good functional outcome in humeral diaphyseal non-union.

LCP is a good implant in achieving union in patients of the younger age group with higher activity levels, with osteoporotic bones and cases of nonunion treated primarily with implants like DCP and intramedullary nails.

This study was conducted at a single center so a larger randomized multicentric trial is needed to further improve the interpretation of the results. Results of this study are comparable with the reported literatures [20-22] in terms of functional outcome and complication rates in both the groups. LCP fixation with bone grafting is an effective treatment option for non-union of fractures of humerus shaft with comparable functional outcomes and acceptable complications.

Compliance with Ethical Standards

Conflict of Interest: No authors identified on this manuscript or any relations to these authors have any conflicts of interest to report, financial or otherwise.

Ethical Standard Statement: All procedures performed in studies were in accordance with the ethical standards of the institutional and/or national research committee and with the 1964 Helsinki declaration and its later amendments or comparable ethical standards.

Patient Consent: Informed consent was given by all the patients included in this study.

Funding: For this study, there was no source of funding

References

1. Marti RK, Verheyen CC, Besselaar PP (2002) Humeral shaft nonunion: evaluation of uniform surgical repair in fifty-one patients. *J Orthop Trauma* 16(2): 108-115.
2. Healy WL, White GM, Mick CA, Brooker AF, Weiland AJ (1987) Nonunion of the humeral shaft. *Clin Orthop* 219: 206-213.
3. Foulk DA, Szabo RM (1995) Diaphyseal humerus fractures: natural history and occurrence of nonunion. *Orthopedics* 18(4): 333-335.
4. Cleveland KB (2008) Delayed union and non union of fractures. In: Canale ST, Beaty JH (eds) *Campbell's operative orthopaedics*, 11th (Edn.), Mosby, Philadelphia 3: 3529-3565.
5. Jupiter JB, Wyss H (2010) Stable fixation of osteoporotic fractures and nonunions in the upper limb-life before the "locking plate". *Acta Chir Orthop Traumatol Cech* 77(5): 361-364.
6. Patel VR, Menon DK, Pool RD, Simonis RB (2000) Nonunion of the humerus after failure of surgical treatment management using the Ilizarov circular fixator. *J Bone Joint Surg* 82-B: 977-983.
7. Ring D, Kloen P, Kadzielski J, Helfet D, Jupiter JB (2004) Locking compression plates for osteoporotic nonunions of the diaphyseal humerus. *Clin Orthop Relat Res* 425: 50-54.
8. Nadkarni B, Srivastav S, Mittal V, Agarwal S (2008) Use of locking compression plates for long bone nonunions without removing existing intramedullary nail: Review of literature and our experience. *J Trauma* 65(2): 482-486.
9. Constant CR, Murley AH (1987) A clinical method of functional assessment of the shoulder. *Clin Orthop Relat Res* 214: 160-164.
10. Sarmiento A, Zagorski JB, Zych GA, Latta LL, Capps CA (2000) Functional bracing for the treatment of fractures of the humeral diaphysis. *J Bone Joint Surg* 82(4): 478-486.
11. Rubel I, Kloen P, Campbell D, Schwartz M, Liew A, et al. (2002) Open Reduction and Internal Fixation of Humeral Non-unions, A Biochemical and Clinical Study. *J Bone Joint Surg* 84: 1315-1322.
12. Putti AB, Uppin RB, Putti BB (2009) Locked intramedullary nailing versus dynamic compression plating for humeral shaft fractures. *J Orthop Surg (Hong Kong)* 17(2): 139-141.
13. Denies E, Nijs S, Sermon A, Broos P (2010) Operative treatment of humeral shaft fractures. Comparison of plating and intramedullary nailing. *Acta Orthop Belg* 76: 735-742.
14. Kiran M, Jee R (2010) Ilizarov's method for treatment of nonunion of diaphyseal fractures of the humerus. *Indian J Orthop* 44: 444-447.
15. Singh HP (2004) Humeral nonunion after failure of plate fixation, managed by Ilizarov fixator. *Indian J Orthop* 38: 107-109.
16. Niall DM, O'Mahony J, McElwain JP (2004) Plating of humeral shaft fractures – Has the pendulum swung back? *Injury* 35: 580-586.
17. McCormack RG, Brien D, Buckley RE, McKee MD, Powell J, et al. (2000) Fixation of fractures of the shaft of the humerus by dynamic compression plate

- or intramedullary nail. A prospective, randomised trial. *J Bone Joint Surg Br* 82(2): 336-339.
18. Zhang CQ, Cheng XG, Sheng JG, Li HS, Su Y, et al. (2008) (The surgical technique and follow-up of the treatment with locking internal fixation on long bone non-union extremities.) *Zhonghua Wai Ke Za Zhi* 46(7): 510-513.
 19. Kumar MN, Ravindranath VP, Ravishankar MR (2013) Outcome of locking compression plates in humeral shaft nonunions. *Indian J Orthop* 47(2): 150-155.
 20. Wu CC, Shih CH (1992) Treatment for nonunion of the shaft of the humerus: comparison of plates and Seidel interlocking nails. *Can J Surg* 35(6): 661-665.
 21. Idoine JD, French BG, Opalek JM, DeMott L (2012) Plating of acute humeral diaphyseal fractures through an anterior approach in multiple trauma patients. *J Orthop Trauma* 26(1): 9-18.
 22. Kesemenli CC, Subasi M, Arslan H, Necmioglu S, Kapukaya A (2002) Treatment of humeral diaphyseal nonunions by interlocked nailing and autologous bone grafting. *Acta Orthop Belg* 68(5): 471-475.